

American Society of Echocardiography Guidelines and Standards for Performance of the Fetal Echocardiogram

A statement of the Pediatric Council of the American Society of Echocardiography represented by, Jack Rychik, MD, Nancy Ayres, MD, Bettina Cuneo, MD, Nina Gotteiner, MD, Lisa Hornberger, MD, Philip J. Spevak, MD, and Mary Van Der Veld, MD

INTRODUCTION

Fetal echocardiography is the ultrasonic evaluation of the human fetal cardiovascular system. General antepartum obstetrical ultrasound has become a standard part of gestational care and is commonly used for the determination of fetal age, size, gender, or well-being and for the detection of congenital anomalies. A variety of maternal or fetal disorders may result in abnormality of the fetal cardiovascular system to a degree which demands evaluation at a level above and beyond that attainable with standard antepartum obstetrical ultrasound. In these circumstances, a fetal echocardiogram should be performed.

Improved operator skill amongst physicians performing general antepartum obstetrical ultrasound, in combination with increased sensitivity of present day ultrasound systems, has resulted in improved detection of fetal cardiovascular abnormalities and increased requirements for more detailed evaluation. Congenital heart disease is the most common congenital anomaly found in the human.¹ As the detection rates for congenital anomalies continue to increase, the demand for fetal echocardiography has grown. Accurate diagnosis of congenital heart disease via fetal echocardiography provides many benefits. It allows for a smooth transition between the pre- and post-natal states, with the opportunity to provide immediate care at birth, thereby avoiding the onset of hemodynamic compromise. Recent

studies suggest improved physiological state after birth and improved surgical outcome for infants who have had prenatal diagnosis via fetal echocardiography.^{2,3} In addition, accurate diagnosis via fetal echocardiography allows for appropriate counseling to take place and for parents to take the opportunity to learn about the cardiac anomaly. This knowledge can allay parental fears, improve psychological state, and bolster coping skills in dealing with the birth of a child with life-threatening cardiovascular illness.⁴

Fetal echocardiography can also contribute to improved understanding when applied to cardiovascular abnormalities unrelated to congenital heart disease. Such data, when presented in a multidisciplinary format, can help elucidate the pathophysiology of a variety of disorders and can be used to both guide and monitor disease therapy.

Performance and interpretation of fetal echocardiography requires a unique set of advanced skills and knowledge. The fetal heart is of small size and dynamic in nature. A myriad of complex anatomical and physiological derangements are possible. The American Institute of Ultrasound in Medicine⁵ and the American College of Radiology⁶ have recommended performance of a 4-chamber view of the heart as part of the standard for an antepartum obstetrical ultrasound. However, studies have shown that when using the 4-chamber view alone, important congenital heart disease may go unrecognized.⁷ Addition of right and left ventricular outflow tract and great artery visualization improves the yield allowing for more effective screening for congenital heart disease,⁸⁻¹⁰ however many anomalies can still be missed. Hence general antenatal obstetrical ultrasound can function as a screen for fetal cardiovascular disorders; suspicion or detection of a fetal cardiovascular abnormality requires referral for a more comprehensive evaluation to a physician with expertise in fetal echocardiography. Well-trained pediatric cardiologists, maternal-fetal medicine specialists, or obstetrical radiologists who have acquired the appropriate knowledge base and skills as outlined below may perform fetal echocardiography.

The purpose of this statement from the American Society of Echocardiography is to define the distin-

From The Children's Hospital of Philadelphia (J.R.), Texas Children's Hospital, Houston (N.A.), Hope Children's Hospital, Oak Lawn, Ill (B.C.), Children's Memorial Hospital, Chicago (N.G.), University of California San Francisco (L.H.), Johns Hopkins Medical Center, Baltimore (P.J.S.), and Mott Children's Hospital, Ann Arbor, Mich (M.V.).

Address reprint requests to the American Society of Echocardiography, 1500 Sunday Drive, Suite 102, Raleigh, NC 27607 (919) 787-5574.

J Am Soc Echocardiogr 2004;17:803-10.
0894-7317/\$30.00

Copyright 2004 American Society of Echocardiography, Property of ASE. Reprint of these documents, beyond single use, is prohibited without the prior written authorization of the ASE.

doi:10.1016/j.echo.2004.04.011

guishing elements of the fetal echocardiogram from other forms of ultrasonic evaluation and to provide guidelines and standards for physician performance and interpretation of fetal echocardiography.

SKILLS AND KNOWLEDGE REQUIRED

Performance and interpretation of fetal echocardiography requires a special set of skills and knowledge. The physician performing and interpreting fetal echocardiography must:

- be able to recognize the full spectrum of simple and complex, acquired and congenital, heart disease and its manifestations and natural history throughout gestation, and recognize the limitations of fetal echocardiography in detecting important associated lesions
- have the skill and ability to apply all modalities of echocardiography including 2-dimensional, M-mode, pulsed-wave, continuous wave, and Doppler color flow mapping in recognizing and evaluating both the normal and abnormal fetal cardiovascular state
- have knowledge of the anatomy and physiology of the cardiovascular system throughout the stages of human development
- have a thorough understanding of the spectrum of fetal arrhythmias and the ability to utilize the spectrum of echocardiographic modalities for their assessment
- be knowledgeable in the principles of biological ultrasound instrumentation and its application in human pregnancy
- have a thorough understanding of maternal-fetal physiology as well as maternal conditions that may affect the developing fetus
- be familiar with the latest developments in obstetrical diagnostics, which include invasive and non-invasive tests available throughout pregnancy
- have knowledge of the growing field of invasive fetal intervention and its possible effects on the fetal cardiovascular system.

Specific training requirements and maintenance of competency guidelines have been developed by the American College of Cardiology in conjunction with the American Heart Association and American Society of Echocardiography and are endorsed by our group.¹¹

The physician performing and interpreting fetal echocardiography should have access to a multidisciplinary team with expertise in maternal-fetal medicine, genetics, neonatology, pediatric surgery, pediatric cardiology, and pediatric cardiac surgery, with availability for consultative services and advice. Oftentimes the physician performing fetal echocardi-

Table 1 Examples of indications for fetal echocardiography

| Maternal indications | Fetal indications |
|---|--|
| • Family history of CHD | • Abnormal obstetrical ultrasound screen |
| • Metabolic disorders (eg, diabetes, PKU) | • Extracardiac abnormality |
| • Exposure to teratogens | • Chromosomal abnormality |
| • Exposure to prostaglandin synthetase inhibitors (eg, ibuprofen, salicylic acid, indomethacin) | • Arrhythmia |
| • Rubella infection | • Hydrops |
| • Autoimmune disease (eg, SLE, Sjögren's) | • Increased first trimester nuchal translucency |
| • Familial inherited disorders (Ellisvan Creveld, Marfan, Noonan's, etc) | • Multiple gestation and suspicion of twin-twin transfusion syndrome |
| • In vitro fertilization | |

CHD, Congenital heart disease; PKU, phenyl ketonuria; SLE, systemic lupus erythematosus.

ography will also offer counseling to the family of the fetus. In these circumstances, the physician offering counsel must have a thorough knowledge base of all management strategies and be familiar with current outcomes for treatment of congenital and acquired cardiovascular disease.

INDICATIONS

Indications for fetal echocardiography can be separated into maternal and fetal indications. Examples are listed in Table 1.

There are presently no strong prenatal markers available for identifying the fetus with congenital heart disease. Family history of congenital heart disease or the presence of a chromosomal anomaly are relative risk factors. Increased nuchal translucency present at 10 to 13 weeks gestation has been associated with an increased risk of congenital heart disease, even in the absence of chromosomal anomaly.¹² Recent reports indicate up to a 3-fold increase in the prevalence of congenital heart disease over the general population in infants conceived via intracytoplasmic sperm injection and in-vitro fertilization.¹³

THE FETAL ECHOCARDIOGRAM

Timing of Examination

The optimal timing for performance of a comprehensive transabdominal fetal echocardiogram is 18 to 22 weeks gestation. Images can be more difficult to obtain after 30 weeks gestation, as the ratio of

fetal body mass-to-amniotic fluid increases. Acquiring images of the fetal heart at 15 to 18 weeks is possible; however performing a comprehensive cardiac evaluation study at this age can be difficult and may require repeat assessment at 18 to 22 weeks.

Equipment

Ultrasound systems used for fetal echocardiography should have capabilities for performing 2-dimensional, M-mode, and Doppler imaging. The requirements of fetal echocardiography are more stringent than for the examination of an infant or child with congenital or acquired heart disease. This is due to the increased demands for both spatial and temporal resolution. Anatomic surveys require axial resolution of 1 mm or less and this is particularly important given the small size of critical fetal cardiac structures. Frames rates of 80 to 100 Hz are frequently needed to view important events occurring at heart rates in excess of 140 beats per minute. To meet these requirements, imaging systems need to be optimally configured. In general, system settings are adjusted to minimize persistence and spatial averaging and to increase frame rate. All modalities of Doppler including color, pulse, high pulse repetition frequency, and continuous wave should be available. Tissue Doppler imaging has been recently applied in the assessment of fetal arrhythmia.¹⁴ Harmonic imaging is useful when acoustic penetration is difficult such as in the presence of maternal obesity. Phased array transducers with fundamental frequencies between 4 and 12 MHz are generally used. Curvilinear probes may be helpful given the wider near-field of view. High frequency transducers with a narrower footprint commonly used in echocardiography of infants may also be helpful.

Examination Technique

The essential components of the fetal echocardiogram are listed in Table 2. Although the goal is to achieve visualization of each of the essential components, not all will be visualized in every fetus at every examination. Fetal position in the uterus or increased activity may limit the ability to obtain visualization of each of the components.

The number of vessels in the umbilical cord is counted and Doppler sampling of the umbilical artery and umbilical vein is performed. After establishing the position of the fetus and the right/left and anterior/posterior orientation, an initial survey of the fetus is used to estimate the gestational age and to establish abdominal situs and cardiac position. The presence or absence of fluid in the pericardial, pleural, or peritoneal space should be noted. The position of the inferior vena cava and descending aorta at the level of the diaphragm are established.

Multiple scanning positions and sweeps are necessary to adequately image the fetal heart. Suggested

Table 2 Essential components of the fetal echocardiogram

| Feature | Essential component |
|--------------------------------|---|
| Anatomic overview | Fetal number and position in the uterus Establish stomach position and abdominal situs Establish cardiac position |
| Biometric examination | Cardiothoracic ratio Biparietal diameter Femur length |
| Cardiac imaging views/sweeps | Four-chamber view Four-chamber view angled towards great arteries ("Five-chamber" view) Long-axis view (left ventricular outflow) Long-axis view (right ventricular outflow) Short-axis sweep (cephalad angling includes "3-vessel" view) Caval long-axis view Ductal arch view Aortic arch view |
| Doppler examination | Inferior and superior vena cava Pulmonary veins Hepatic veins Ductus venosus Foramen ovale Atrioventricular valves Semilunar valves Ductus arteriosus Transverse aortic arch Umbilical artery Umbilical vein |
| Measurement data | Atrioventricular valve diameter Semilunar valve diameter Main pulmonary artery Ascending aorta Branch pulmonary arteries Transverse aortic arch Ventricular length Ventricular short-axis dimensions |
| Examination of rhythm and rate | M-mode of atrial and ventricular wall motion Doppler examination of atrial and ventricular flow patterns |

views are described below with a brief explanation of how to achieve the view and the structures generally well seen. Reference sources are available, which illustrate these views in detail.¹⁵ Figures 1 and 2 demonstrate the anatomical correlates to the tomographic imaging planes used for the views described below. The authors recognize that based on operator style, alternative or additional sweeps and views may be utilized to image the various structures of the fetal heart and still accomplish a comprehensive fetal echocardiogram.

Four-chamber view. The 4-chamber view is generally easy to achieve and is useful for identifying the

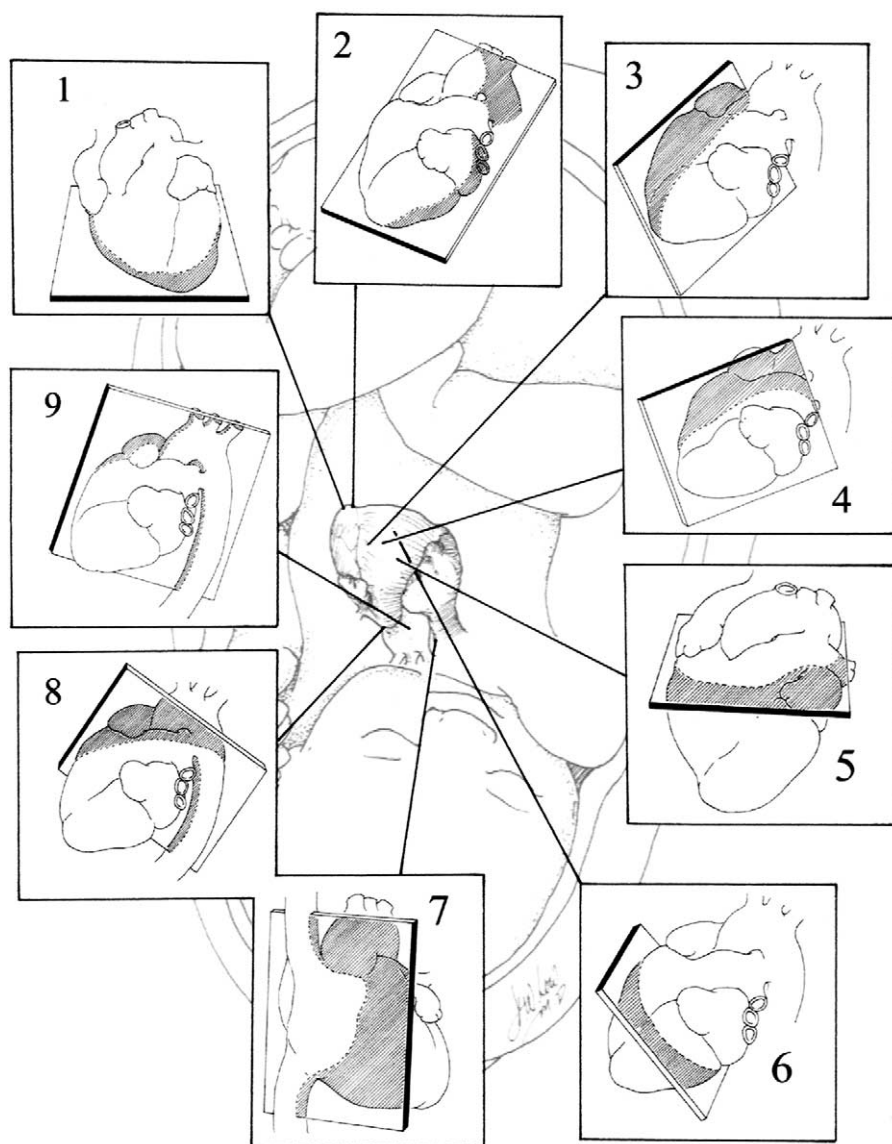


Figure 1 Illustration of the tomographic planes used to image the fetal cardiovascular system. Imaging planes displayed are in a normal human fetus. Starting at the top left, the following views are demonstrated in a clockwise manner: 1, apical (4-chamber) view; 2, apical (5-chamber) view angled towards the aorta; 3, long-axis view of the left ventricular outflow tract; 4, long-axis view of the right ventricular outflow tract; 5, short-axis view at the level of the great vessels; 6, short-axis view with caudal angling at the level of the ventricles; 7, caval long-axis view; 8, ductal arch view; 9, aortic arch view.

atria, ventricles, and respective septae (Table 3). The diameters of the mitral and tricuspid valve annuli are measured. The lengths of the left and right ventricle can also be measured. Numerous standards for dimensional measures based on gestational age have been published.¹⁶⁻¹⁹ The view is inadequate for determining the conotruncus and in particular, excluding transposition of the great arteries. From the standard 4-chamber view, one should sweep posteriorly to demonstrate the coronary sinus and then anteriorly to identify the aorta. Often-

times, the pulmonary veins can be identified entering the left atrium posteriorly.

Short-axis view. The short-axis view is obtained by scanning perpendicular to the long axis of the heart (Table 4). It is an excellent view for identifying the return of the pulmonary veins. In general, the connections of both lower lobe veins can be visualized. The upper pulmonary veins may be identified as they course directly beneath the branch pulmonary arteries. Sweeping cranially, one can measure right ventricular and left ventricular diastolic dimen-

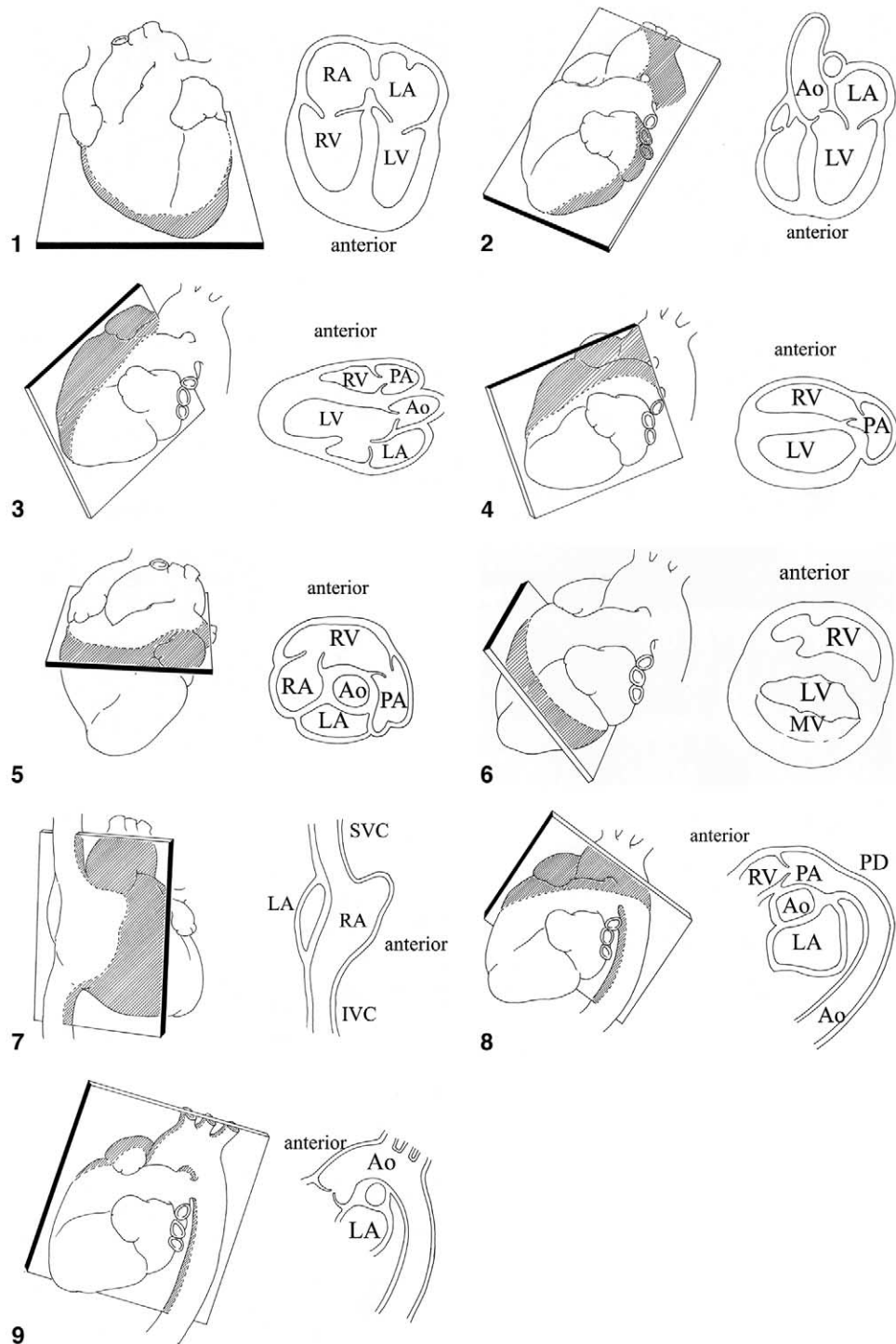


Figure 2 Illustrations of the anatomical correlates for each of the designated tomographic imaging planes used for imaging of the fetal cardiovascular system. Each numbered view relates to the clockwise illustration of the fetal heart in Figure 1. *Ao*, Aorta; *IVC*, inferior vena cava; *LA*, left atrium; *LV*, left ventricle; *MV*, mitral valve; *PA*, pulmonary artery; *PD*, patent ductus; *RA*, right atrium; *RV*, right ventricle; *SVC*, superior vena cava.

Table 3 Structures viewed in the 4- and 5- chamber view

- Atrial and ventricular size
- Atrial and ventricular septae
- Atrioventricular size and function
- Coronary sinus
- Ventricular function in long axis
- Semilunar valve function (may not, however, be optimal to differentiate aorta from main pulmonary artery)
- Pulmonary veins

Table 4 Structures viewed in the cardiac short-axis sweep

- Pulmonary venous return
- Inferior vena cava and hepatic veins
- Ventricular short-axis dimensions
- Ventricular-arterial relationship
- Right ventricular outflow tract
- Branch pulmonary arteries and origin
- Caval connections
- Innominate vein
- Ductus arteriosus
- Determination of arch sidedness and branching

sions. These measurements should be made at the level of the tips of the papillary muscles of the left ventricle. Even more cranially, one can identify the main pulmonary artery as it supplies the branch pulmonary arteries. Identification of the branch pulmonary arteries facilitates determination of the conotruncus. The superior vena cava can be identified crossing anterior to the ipsilateral branch pulmonary artery. Even more superiorly, the innominate vein is noted and as well, the branching of the aortic arch and arch sidedness. Sweeping inferiorly one can demonstrate the connection of the inferior vena cava and hepatic veins with the right atrium. A cross-sectional view obtained at the level of the superior mediastinum provides an image of the "3-vessel view." In this plane the relationship and size differences between the superior vena cava, the ascending aorta, and main pulmonary artery can be recognized. The main pulmonary artery is more anterior and to the left of the other structures, and tends to have a larger diameter. The ascending aorta is the next, more rightward structure that is positioned slightly posterior relative to the main pulmonary artery. The superior vena cava is the most posterior and rightward vessel of the 3. Slight discrepancies in the position or size of these 3 vessels can identify subtle pathology of the outlets and arches. Anterior to the 3 vessels is the thymus, which wraps over the anterior aspect of the superior mediastinum.

Cardiac long-axis view. The long-axis view is aligned with the left ventricular outflow tract (Table 5). The continuity between the mitral and aortic valves and the absence of sub-aortic conus is noted. The size of the ascending aorta is measured. Sweep-

Table 5 Structures viewed in the cardiac long-axis sweep

- Superior and inferior vena cava
- Left ventricular outflow tract
- Ascending aorta
- Great vessel connection and size
- Ductus arteriosus and proximal ductal arch

Table 6 Structures viewed in the caval long-axis view

- Superior vena cava
- Inferior vena cava and eustachian valve
- Patent foramen ovale
- Right pulmonary artery

Table 7 Structures viewed in the ductal and aortic arch views

- Main pulmonary artery
- Branch pulmonary arteries
- Patent ductus arteriosus and direction of flow
- Aortic arch dimension (ascending, transverse, isthmus, and descending)
- Direction of flow in the aortic arch

ing to the right allows visualization of both cavae (although these structures are better visualized in the caval view described below).

Caval long-axis view. The caval long-axis view is obtained with the imaging plane parallel to the caval connections to the right atrium (Table 6). Continuity of the inferior vena cava as it passes through the liver is established. The septum primum is seen extending into the left atrium. Color Doppler interrogation demonstrates the normal right to left flow across the foramen ovale, which is reversed in lesions of critical left heart hypoplasia.²⁰

Ductal view and aortic arch view. The ductal view is obtained when the imaging plane is aligned with the right ventricular outflow tract and main pulmonary artery. The aortic arch is obtained with the beam aligned from anterior right of the fetal chest to posterior left of the fetal chest (Table 7). In the ductal view, the main pulmonary artery, and ductal arch are well seen and main pulmonary artery size is easily measured. The direction of ductal flow is appreciated and the velocity recorded. Sweeping to either side may allow visualization of the branch pulmonary arteries. As the ductus connects with the descending aorta, the isthmus is well seen and the direction of flow established.²¹ In the aortic arch view, antegrade flow through the ascending aorta, transverse arch, and descending aorta is established with color Doppler interrogation.

Heart rate and rhythm. The rate and mechanism of rhythm is established by identifying mechanical events associated with both atrial and ventricular systole. Atrial systole is identified with either an

M-mode of the lateral atrial wall or atrial appendage,²² pulse Doppler interrogation of the outflow tract at a location where atrioventricular valve inflow is detected,²³ or pulse tissue Doppler of the atrial wall.¹⁴ The identification of atrioventricular valve inflow serves as a proxy for atrial systole. Ventricular systole can be identified with M-mode of the ventricular free wall or aortic valve or again, using pulse Doppler interrogation of the outflow tract or tissue Doppler of the ventricular myocardium. Doppler flow in the outflow tract serves as a proxy for ventricular systole. Measurement of the time interval between two successive beats allows calculation of rate. Simultaneous interrogation of left ventricular inflow and outflow allows assessment of atrioventricular conduction and the “mechanical” PR interval.²³

ULTRASOUND SAFETY DURING PREGNANCY

The standard fetal echocardiographic examination utilizes all modalities of diagnostic ultrasound including 2-dimensional (B-mode) imaging, Doppler, and Doppler color flow mapping. Ultrasound energy expenditures increase with each modality used and are most intense when Doppler color flow mapping is applied to a small region of interest, as is commonly the case when examining the structures of the fetal heart.²⁴ Hence special consideration should be given to the use of ultrasound energy in the developing fetus. While theoretical concerns exist, to date there have been no confirmed harmful effects detected.²⁵ Those performing fetal echocardiography should be aware of these effects and should limit power output and time of exposure to no more than that which is absolutely necessary to complete the examination.

As ultrasound technology has advanced and new modalities added, power output on newer systems has changed. In 1985, the Food and Drug Administration 510(K) guide strictly limited ultrasound power output on imaging systems. However, since 1992 much greater output levels have been allowed in conjunction with a display of power output, thereby placing responsibility upon the user to make educated decisions regarding relative risk of a particular modality.²⁶ Potential bioeffects of ultrasound energy can be categorized as thermal, or relating to increase in temperature in the region of insonation, or mechanical, relating primarily to cavitation.²⁷ Current ultrasound systems allow for display of potential increase in temperature via the thermal index (TI) assigned for either soft-tissue (TIS), or bone (TIB). The TI represents an estimate of the temperature rise in the field and is approximately proportional to the temperature increase in degrees Celsius (eg, a TI of 2 means that the

maximum temperature increase that may result from the exposure at those ultrasound system settings is 2°C). The risk of mechanically induced ultrasound damage is displayed by the mechanical index (MI), which is defined as the ratio of maximal peak rarefactional pressure to the square root of the ultrasound frequency. The risk of mechanical injury rises with increasing MI.

As newer modalities such as Doppler applications assessing tissue motion and real-time 3-dimensional imaging continue to develop, bioeffects on the fetus will need to continue to be monitored. As there are no strictly defined limits established, use of ultrasound energy in fetal echocardiography is best expressed by the “ALARA” principle—as low as reasonably achievable.²⁸

SUMMARY

The fetal echocardiogram is a unique ultrasound examination, which differs from the antenatal obstetrical ultrasound and from the conventional echocardiogram in the infant, child, or adult. A unique, high level set of skills and knowledge is required in order to perform this test. In this statement, we outline the indications and essential performance components of the fetal echocardiogram, as well as highlight the importance of operator cognizance of potential safety concerns. This statement contributes to the establishment of a standard for performance of the fetal echocardiogram, as the use of this valuable assay continues to expand in the future.

We wish to acknowledge Dr David Low for his artistic contributions to this report.

REFERENCES

1. Hoffman JI, Kaplan S. The incidence of congenital heart disease. *J Am Coll Cardiol* 2002;39:1890-900.
2. Verheijen PM, Lisowski LA, Stoutenbeek P, Hitchcock JF, Brenner JJ, Cope JA, et al. Prenatal diagnosis of congenital heart disease affects preoperative acidosis in the newborn patient. *J Thorac Cardiovasc Surg* 2001;121:798.
3. Tworetzky W, McElhinney DB, Reddy VM, Brook MM, Hanley FL, Silverman NH. Improved surgical outcome after fetal diagnosis of hypoplastic left heart syndrome. *Circulation* 2001;103:1269-73.
4. Sklansky M, Tang A, Levy D, Grossfeld P, Kashani I, Shaughnessy R, et al. Maternal psychological impact of fetal echocardiography. *J Am Soc Echocardiogr* 2002;15:159-66.
5. Standards for the Performance of the Antepartum Obstetrical Ultrasound Examination. Copyright 1994, by the American Institute of Ultrasound in Medicine.
6. American College of Radiology Standard for the Performance of Antepartum Obstetrical Ultrasound.
7. Nelson NL, Filly RA, Goldstein RB, Callen PW. The AIUM/ACR antepartum obstetrical sonographic guidelines: expecta-

- tions for detection of anomalies. *J Ultrasound Med* 1993;4:186-96.
8. Carvalho JS, Mavrides E, Shinebourne EA, Campbell S, Thilaganathan B. Improving the effectiveness of routine prenatal screening for major congenital heart defects. *Heart* 2002;88:387-91.
 9. Buskens E, Grobbee DE, Frohn-Mulder IME, Stewart PA, Juttman RE, Wladimiroff JW, et al. Efficacy of routine fetal ultrasound screening for congenital heart disease in normal pregnancy. *Circulation* 1996;94:67-72.
 10. Stumpflen I, Stumpflen A, Wimmer M, Bernaschek G. Effect of detailed fetal echocardiography as part of routine prenatal ultrasonographic screening on detection of congenital heart disease. *Lancet* 1996;348:854-7.
 11. Quinones MA, Douglas PS, Foster E, Gorcsan J, Lewos JF, Pearlman AS, et al. ACC/AHA clinical competence statement on echocardiography: a report of the American College of Cardiology/American Heart Association/American College of Physicians-American Society of Internal Medicine task force on clinical competence (committee on echocardiography). *J Am Coll Cardiol* 2003;41:687-708.
 12. Ghi T, Huggon IC, Zosmer N, Nicolaidis KH. Incidence of major structural cardiac defects associated with increased nuchal translucency but normal karyotype. *Ultrasound Obstet Gynecol* 2001;18:610-4.
 13. Hansen M, Kurinczuk JJ, Bower C, Webb S. The risk of major birth defects after intracytoplasmic sperm injection and in vitro fertilization. *N Engl J Med* 2002;346:725-30.
 14. Rein AJ, O'Donnell C, Geva T, Nir A, Perles Z, Hashimoto I, et al. Use of tissue velocity imaging in the diagnosis of fetal cardiac arrhythmias. *Circulation* 2002;106:1827-33.
 15. Allan L, Hornberger L, Sharland G, editors. *Textbook of fetal cardiology*. London: Greenwich Medical Media; 2000.
 16. Sharland GK, Allan LD. Normal fetal cardiac measurements derived by cross-sectional echocardiography. *Ultrasound Obstet Gynecol* 1992;2:175-81.
 17. Tan J, Silverman NH, Hoffman JIE, Villegas M, Schmidt KG. Cardiac dimensions determined by cross-sectional echocardiography in the normal human fetus from 18 weeks to term. *Am J Cardiol* 1992;70:1459-67.
 18. Schmidt KG, Silverman NH, Van Hare GF, Hawkins JA, Cloez JL, Rudolph AM. Two-dimensional echocardiographic determination of ventricular volumes in the fetal heart. *Circulation* 1990;81:325-33.
 19. Phillipos EZ, Robertson MA, Still KD. The echocardiographic assessment of the human foramen ovale. *J Am Soc Echocardiogr* 1994;7:257-63.
 20. Berning RA, Silverman NH, Villegas M, Sahn DJ, Martin GR, Rice MJ. Reversed shunting across the ductus arteriosus or atrial septum in utero heralds severe congenital heart disease. *J Am Coll Cardiol* 1996;27:481-6.
 21. Fouron JC, Zarelli M, Drblik SP, Lessard M. Normal flow velocity profile of the fetal aortic isthmus through normal gestation. *Am J Cardiol* 1994;74:483-6.
 22. Kleinman C, Donnerstein R, Jaffe C, DeVore G, Weinstein EM, Lynch DC, et al. Fetal echocardiography. A tool for evaluation of in utero cardiac arrhythmias and monitoring of in utero therapy. *Am J Cardiol* 1983;51:237-43.
 23. Glickstein JS, Buyon J, Friedman D. Pulsed Doppler echocardiographic assessment of the fetal PR interval. *Am J Cardiol* 2000;86:236-9.
 24. Kurjak A. Are color and pulsed Doppler sonography safe in early pregnancy? *J Perinat Med* 1999;27:423-30.
 25. Abramowicz JS, Kossoff G, Marsal K, Ter Haar G. Literature review by the ISUOG bioeffects and safety committee. *Ultrasound Obstet Gynecol* 2002;19:318-9.
 26. Deane C, Lees C. Doppler obstetric ultrasound: a graphical display of temporal changes in safety indices. *Ultrasound Obstet Gynecol* 2000;15:418-23.
 27. Miller MW, Brayman AA, Abramowicz JA. Obstetric ultrasonography: a biophysical consideration of patient safety—the “rules” have changed. *Am J Obstet Gynecol* 1998;179:241-54.
 28. International Society of Ultrasound in Obstetrics and Gynecology (ISUOG). Safety statement, 2000. *Ultrasound Obstet Gynecol* 2000;16:594-6.